

日整会誌第 69 卷第 10 号の掲載論文「前腕骨間膜の解剖学的検討」(著者藤田正樹)に次のような誤りがありましたので、訂正するとともにお詫び申し上げます。

941 頁の Fig. 4

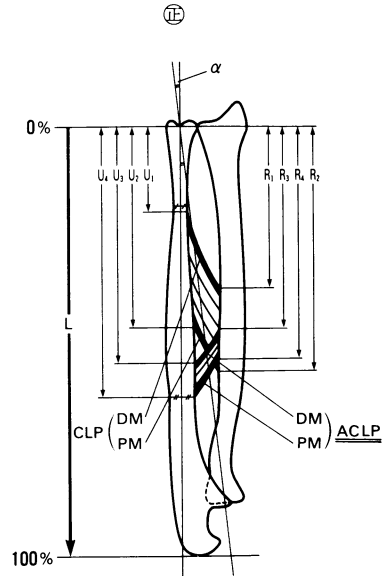
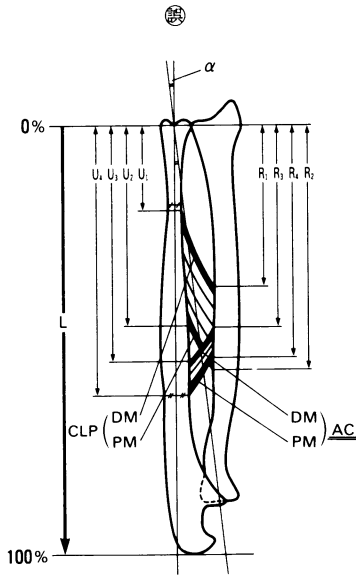


Fig. 4 Radiographic measurements. CLP, cord-like portion; ACLP, accessory cord-like portion; DM, length of distal margin; PM, length of proximal margin; L, forearm length; α , angle of forearm rotational axis; R1 and U1, distal edge of radial and ulnar attachment of cord-like portion as per forearm length; R2 and U2, proximal edge of radial and ulnar attachment of cord-like portion as per forearm length; R3 and U3, distal edge of radial and ulnar attachment of accessory cord-like portion as per forearm length; R4 and U4, proximal edge of radial and ulnar attachment of accessory cord-like portion as per forearm length.

Fig. 4 Radiographic measurements. CLP, cord-like portion; ACLP, accessory cord-like portion; DM, length of distal margin; PM, length of proximal margin; L, forearm length; α , angle of forearm rotational axis; R1 and U1, distal edge of radial and ulnar attachment of cord-like portion as per forearm length; R2 and U2, proximal edge of radial and ulnar attachment of cord-like portion as per forearm length; R3 and U3, distal edge of radial and ulnar attachment of accessory cord-like portion as per forearm length; R4 and U4, proximal edge of radial and ulnar attachment of accessory cord-like portion as per forearm length.